

2

✓

**INSTITUTE OF INDIGENOUS MEDICINE, UNIVERSITY OF COLOMBO, RAJAGIRIYA**  
**BUMS LEVEL II – FIRST SEMESTER EXAMINATION – OCTOBER 2017**

**ANATOMY - III**  
**COURSE CODE – AS 2101**

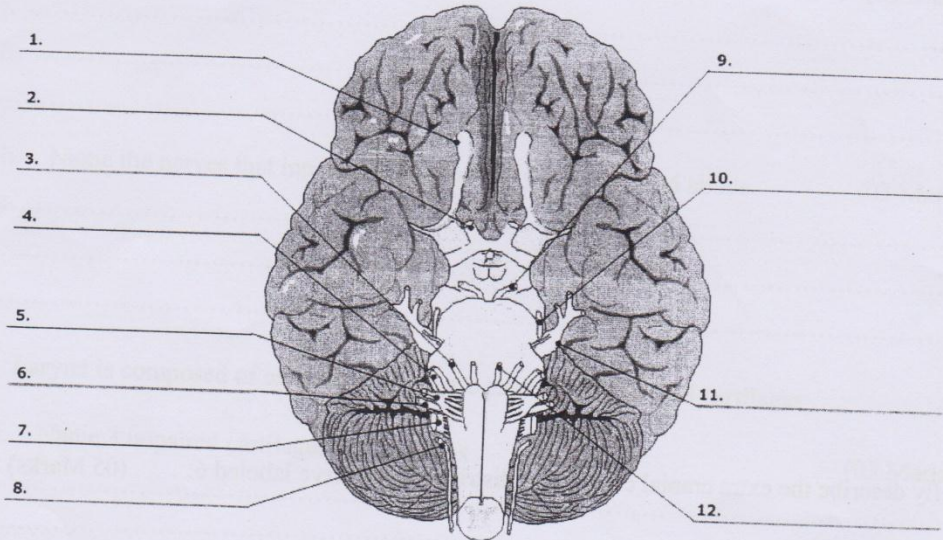
Time: 1 ½ hours  
(1.45 p.m. – 3.15 p.m)

Answer all questions.

Index No

**Part I - Structured Questions**

1. Diagram of the base of the brain given below.



- A. Name the cranial nerves labeled as 3, 9 and 12 respectively.

( 03 Marks)

.....

.....

.....

- B. Name 3 muscles innervated by nerve labeled 3.

(03 Marks)

.....


.....

.....

C. Name the foramina found within the cranial cavity through which following nerves exit. (03 Marks)

- 3. ....
- 5. ....
- 6. ....

D. Draw a labeled diagram of arterial supply of the brain. (06 Marks)



E. Briefly describe the extra cranial course and distribution of nerve labeled 6. (05 Marks)

- .....
- .....
- .....
- .....
- .....
- .....
- .....
- .....
- .....
- .....

2. Pharynx is a musculofascial compartment that communicates with nasal and oral cavities and larynx

A. Describe the superior attachment of the pharynx. (03 Marks)

.....  
.....  
.....  
.....  
.....

B. Pharynx is composed of circular and vertically oriented muscles.

i. Name 3 longitudinal muscles of the pharynx. (03 Marks)

.....  
.....  
.....

ii. Name the nerves that innervate each muscle you mentioned above. (03 Marks)

.....  
.....  
.....

C. Larynx is composed of cartilages. There are paired and unpaired cartilages

i. Name 3 unpaired cartilages of the larynx (03 Marks)

.....  
.....  
.....

ii. Write the histological type of cartilages you mentioned above (03 Marks)

.....  
.....  
.....



iii. Briefly explain the innervation of the larynx

(05 Marks)

.....  
.....  
.....  
.....  
.....  
.....  
.....

**Part II - Essay Questions**

1.

A. Draw a labeled diagram of a transverse section through the vertebral canal and its contents.

(07 Marks)

B. Briefly describe the gross anatomy of the spinal cord, its coverings and vasculature.

(13 Marks)

2. Write short notes on the anatomy of the followings,

A. Cavernous sinus

(08 Marks)

B. Facial artery

(06 Marks)

C. Posterior triangle of the neck

(06 Marks)

23.10.2017

\*\*\*\*\*